

Superoxidized Water Improves Wound Care Outcomes in Diabetic Patients

Nonhealing wounds are affected by opportunistic infection — perhaps the most difficult factor to overcome in any wound care setting.

BY CHERYL M. BONGIOVANNI, PhD

In general, there are three factors that contribute to failure of wounds to heal in a timely manner. These are (1) compromised perfusion resulting in diminished tissue oxygen levels, (2) invading flora and (3) host immunological impairment.^{1,2} We have found that the addition of superoxidized water (Dermacyn; Oculus Innovative Sciences, Petaluma, Calif) to our wound care regimen successfully addresses the first two factors.

Compromised perfusion leading to diminished tissue oxygen is a condition that is best known in diabetics and is of crucial importance in diabetic patients who are further burdened with chronic obstructive pulmonary disease, congestive heart failure and smoking addiction. Chronic tissue oxygen reduction or deprivation readily produces tissue ischemia, which, if not corrected, leads to necrosis and ulcer formation. The excessive, chronic pressure that can occur over bony prominences is common to Charcot arthropathy, long-term care facility residents and spinal cord injury patients. The ulcers thus produced are the sequelae of tissue ischemia. In diabetic patients, the effect of pressure is exacerbated by the shunting of blood flow from precapillary arterioles to postcapillary venules.³

OPPORTUNISTIC INFECTION

Nonhealing wounds of any etiology are further affected by opportunistic infection. This factor alone may become the most difficult to overcome in any wound care setting. The emergence and in many cases predominance of multiple drug-resistant organisms in both the environment and clinical milieus have greatly complicated wound care efforts. Adding to this already-grim scenario is the fact that

antibiotic resistance can be transmitted from one organism to another via plasmids.³

We need to also recognize that nearly all of the organisms commonly referred to as *normal skin flora* can be opportunistic infectious agents given the right set of conditions. These conditions include an open wound that is warm, moist and rich in tissue proteins and sugars. Inappropriate use of occlusive wound dressings may well convert a wound that is colonized with bacteria to one that is frankly infected.

Finally, with multiple drug-resistant organisms now present in the environment, moist bacterial strike-through,⁴ occurring when dressing changes are not performed as frequently as necessary to prevent through-and-through wetting, may result in the presence of a highly resistant, invading organism.

CLINICAL EXAMPLES

Case 1. The first patient is a 62-year-old man who is a heavy smoker but who is nondiabetic. He underwent gastric bypass surgery for relief of extreme, morbid obesity. The procedure allowed him to lose >100 lbs of excess weight, but left him with a serum albumin level <1.5 mg/dL. He scratched his leg on a barbed wire fence and initially ignored the resulting, trivial wound. Within 5 days, the wound became exudative and enlarged, and the patient treated it with over-the-counter antibiotic ointment and adhesive bandages. Two weeks later, he sought medical attention and underwent a varying series of treatment modalities for >13 months. During that time, the wound extended rapidly and dramatically and became circumfer-

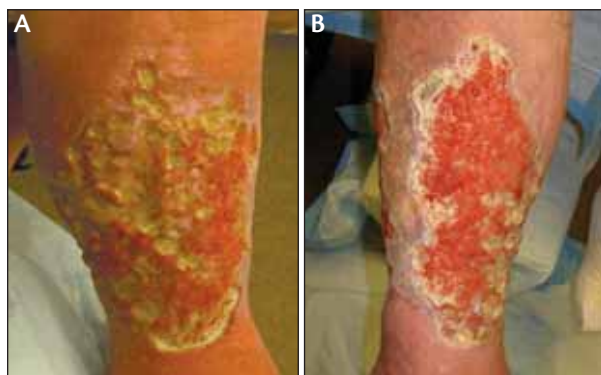

Figure 1. A 62-year-old man without diabetes who was a heavy smoker scratched his leg on barbed wire (A). Within 2 hours of flushing with superoxidized water under pressure, soaking in superoxidized water and wound dressing, there was a clear reduction in bioburden (B).

ential roughly 5 months prior to his referral to the specialty wound clinic. At the time of referral, the patient had been advised to undergo above-knee amputation (Figure 1A).

We cultured the wound and found several *Pseudomonas* species, two of which were not sensitive to any of the antibiotics tested. We thoroughly flushed the wound with superoxidized water under 8 pounds per square inch (psi) of pressure to remove crusted matter and disrupt the abundant, mucopolysaccharide biofilm. We then used several liters of superoxidized water to soak the leg for 30 minutes. We dressed the wound with antimicrobial gauze and constructed an overlying, moderately compressive bandage system. Within 24 hours, we were able to see marked

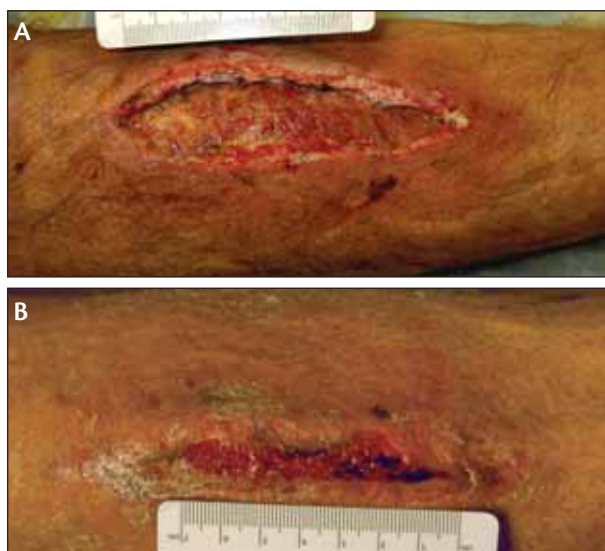

Figure 2. A 53-year-old man sustained an abrasion to his shin (A). By day 8 the lesion was largely resolved following flushing with superoxidized water and dressing (B).

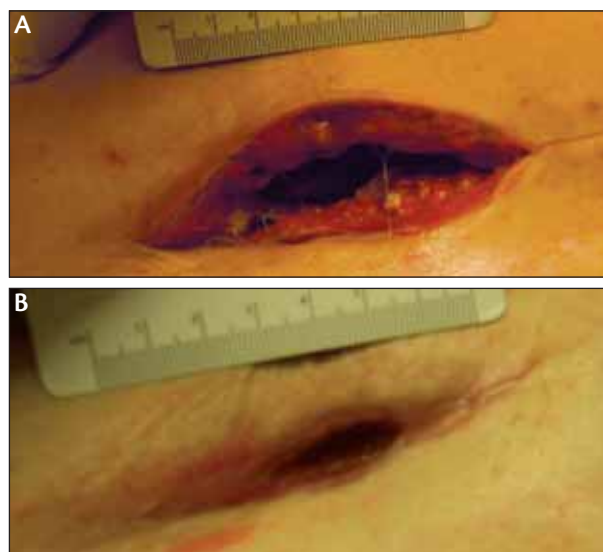


Figure 3. A 19-year-old woman with gestational diabetes delivered via C-section. The site dehiscid completely (A). After 21 days of flushing the wound cavity and a loose packing of the wound, the lesion was closed completely (B).

improvement in wound bed perfusion and a clear reduction in bioburden (Figure 1B).

Case 2. A 53-year-old nonsmoker with type 2 diabetes sustained an abrasion to his shin while at work. Because this was an on-the-job injury, the patient was immediately taken to an urgent-care facility where the physician cleaned the abrasion and dressed it with antibiotic ointment. Within 5 days, the leg was swollen, red, hot, indurated and the abraded area was heavily exudative with green foul matter. The patient was referred to a surgeon who drained a large abscess. Cultures of the abscess material were positive for methicillin-resistant *Staphylococcus aureus* (MRSA), and the patient went on to receive 30 days of IV vancomycin treatment. Repeat cultures of the nonhealed lesion were positive for vancomycin-resistant *Staphylococcus aureus*. At the time of referral (Figure 2A), the patient had been out of work for nearly 2 months, and the wound was exhibiting margin necrosis. We flushed the wound with copious amounts of superoxidized water and dressed it with an antimicrobial gauze that had been moistened with superoxidized water. A bulky, noncompressive bandage was applied, and by day 8, the lesion was largely resolved (Figure 2B).

Case 3. A 19-year-old woman with gestational diabetes delivered via C-section. The surgical site dehiscid completely within 3 days. Cultures were positive for MRSA, and at the time of referral (Figure 3A), the woman had undergone 30 days of IV vancomycin administration. The wound was 14 cm deep and peritoneal sutures were visible. We flushed the wound cavity with 1,000 cc of superoxidized water

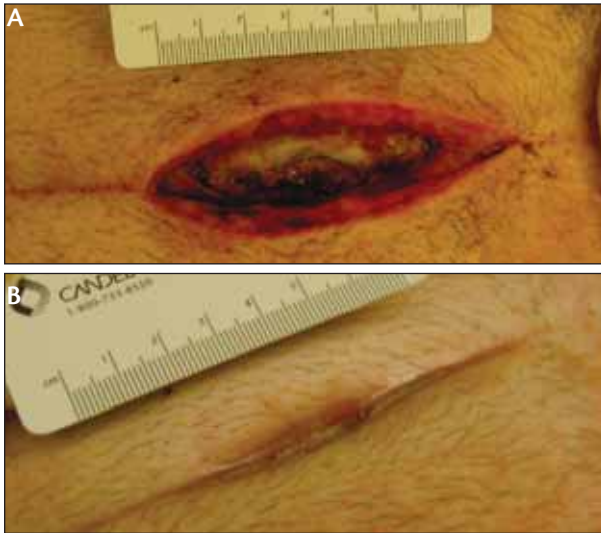

Figure 4. A 49-year-old cholecystectomy patient had a subsequent infection and abdominal wall abscess (A). Only five dressing changes were needed in addition to flushing with superoxidized water to heal the wound (B).

delivered under 8 psi pressure. We loosely packed the wound with antimicrobial gauze and used more of the same as a bulky, overlying bandage. We repeated this treatment twice weekly. By day 21, the lesion was closed completely (Figure 3B).

Case 4. A 49-year-old man underwent cholecystectomy with subsequent infection and abdominal wall abscess. After surgical drainage of the abscess, the man underwent 2 weeks of IV antibiotic administration that failed to clear the infection (Figure 4A). We flushed the wound cavity with superoxidized water under pressure and loosely packed it with antimicrobial gauze moistened with superoxidized water. Only five dressing changes were necessary to heal this wound completely (Figure 4B).

Case 5. A 66-year-old, insulin-dependent diabetic man had an 18-month history of ulceration and infection under the left second metatarsal head. At the time of referral (Figure 5A), the lesion had been expanding despite regular

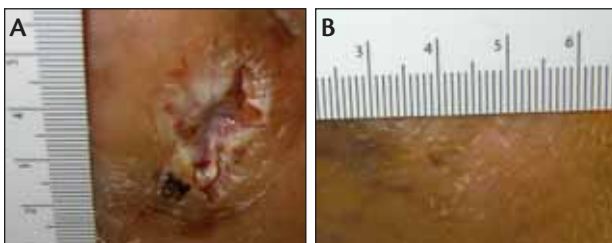


Figure 5. A 66-year-old insulin-dependent man had a history of ulceration (A). The wound healed rapidly after it was flushed with superoxidized water and the patient wore an offloading sandal (B).

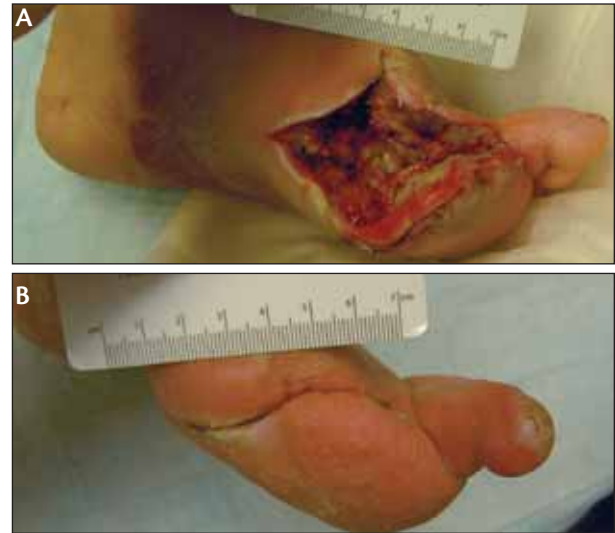

Figure 6. A 45-year-old insulin-dependent woman had ray amputation secondary to developing a nonhealing ulcer and gangrene (A). The wound was soaked in superoxidized water and dressed. By day 40, the wound was healed (B).

care and antibiotic administration. We flushed the lesion with superoxidized water and provided the patient with an offloading sandal. The combination of offloading, antibiotics via superoxidized water only, vascular enhancement caused by the superoxidized water administration and insititution of glycemic control resulted in rapid healing (Figure 5B).

Case 6. A 45-year-old, insulin-dependent diabetic woman underwent ray amputation secondary to development of a nonhealing plantar ulcer and digital gangrene. At the time of referral (Figure 6A), the amputation site had dehisced, and the wound was infected with a *Pseudomonas* species that did not respond to 30 days of IV antibiotic administration. Exposed bone and necrotic soft tissue were apparent at the deepest wound sites. We soaked the wound in superoxidized water for 30 minutes daily for 7 days, then reduced the frequency of treatment to twice weekly. The wound was dressed with antimicrobial gauze and bandaged with more of the same. By day 10, we were able to begin mechanical approximation of the wound edges, and by day 40, healing was complete (Figure 6B).

Case 7. This patient is a 58-year-old, insulin-dependent, diabetic man who is a very heavy smoker with advanced neuropathy. He was initially referred for treatment of two small diabetic ulcers on the lateral aspect of his left foot. On one occasion, he got his bandage wet and attempted to dry it himself with a blow-dryer. This resulted in second- and third-degree burns to the plantar surfaces of his toes (Figure 7A). We used daily soaks in superoxidized water to prevent infection and accelerate development of neovascularity. Within 30 days, the burns had improved sufficiently

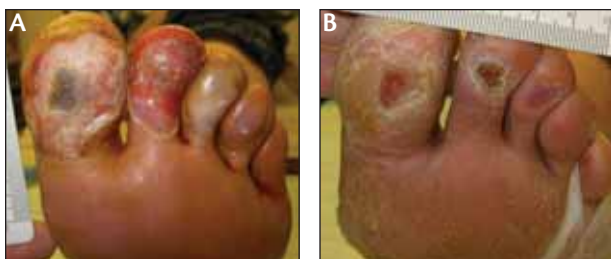

Figure 7. This insulin-dependent, heavy smoker had small ulcers and subsequent second- and third-degree burns (A). Daily soaks in superoxidized water healed the wounds enough for the patient to return to his primary care provider (B).

to enable this patient to return to his primary care provider for ongoing care (Figure 7B).

Case 8. This 54-year-old, insulin-dependent woman is also a heavy smoker. Secondary to severe neuropathy, she did not feel pressure from ill-fitting shoes resulting in a pressure ulcer (Figure 8A). Despite the presence of infection with *Escherichia coli*, daily washes with superoxidized water and dressing with antimicrobial materials resulted in complete healing within 12 days (Figure 8B).

ADDITIONAL TREATMENT PROTOCOLS

Generally, all treatment protocols will include culture and antibiotic sensitivity determinations for all flora; clean, soak and/or flush the wound with superoxidized water; pack, dress, bandage the wound with antimicrobial materials; secure dressings/bandages without allowing adhesive skin contact or using porous materials only; and determine the frequency of dressing changes/treatment interventions by considering the condition of the wound and its exudate.

For diabetic plantar ulcers, treatment protocols will also include offloading the region of the wound, reducing callus around the wound, avoid packing the wound cavity, moisturize the surrounding tissue without introducing the moisturizing agent into the wound cavity itself and preventing ulcer recurrence by construction of appropriate footwear.

For venous leg ulcers, treatment protocols will also include constructing compression bandages to extend from the metatarsal heads to the knee, compression pressure to levels less than ankle arterial pressure, cover compression bandage with cotton stockinette to prevent the bandage from sticking and to avoid adhesive contact with skin.

For dehisced surgical wounds, treatment protocols will also include the following: avoid tight packing, mechanically close the wound with steristrips over light packing then, later, to approximate skin edges; use Montgomery straps for very large, very deep, dehisced abdominal wounds.

For burns, treatment protocols will include avoidance of petrolatum-based ointments/dressings, flushing with copious amounts of superoxidized water as often as every

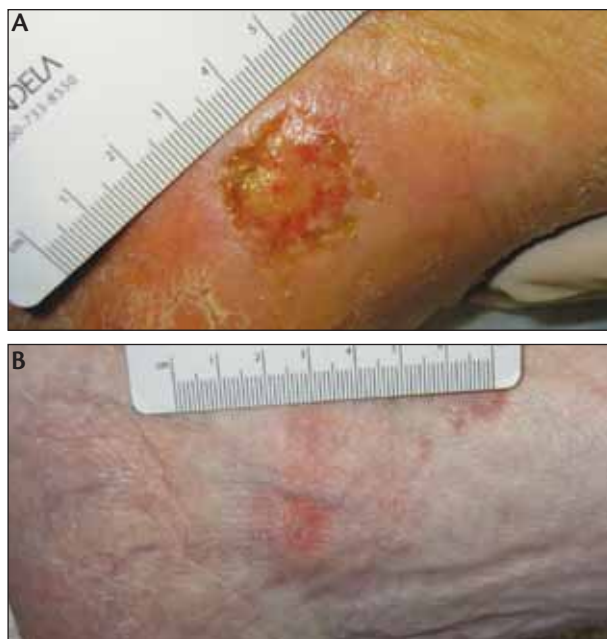

Figure 8. A 54-year-old insulin-dependent woman with a pressure ulcer and severe neuropathy (A). Despite the presence of *E. coli*, daily washes with superoxidized water and dressing resulted in complete healing within 12 days (B).

2 hours and avoidance of moist bacterial strike-through by keeping external bandages dry.

Superoxidized water is effective in reducing bacterial load,⁵ enhancing local blood supply, accelerating development of neovascularity and providing a wound environment that is hostile to opportunistic organisms.

Although superoxidized water is an extremely effective agent in wound management, it will not replace administration of good wound care practices. A multidisciplinary approach to wound care will include assertion of glycemic control, appropriate systemic antibiotics, nutritional amendment and attention to the overall social, medical and economic needs of the patient. ■

Cheryl M. Bongiovanni, PhD, is director of the Vascular Laboratories/Wound Clinics at Lake District Hospital, in Lakeview, Oregon. She discloses that she does not have a financial interest in the company or product mentioned. She may be reached at Cbongi1@aol.com or 541-947-7299.



1. Bakker, DJ. Hyperbaric oxygen therapy and the diabetic foot. *Diabetes Metab Res Rev* 2000;16:S55-58.
2. Zamboni WA, Browder LK, Martinez J. Hyperbaric oxygen and wound healing. *Clin Plastic Surg*. 2003;30:67-75.
3. Thomas S. MRSA and the use of silver dressings: Overcoming bacterial resistance. *World Wide Wounds*. 2004. Available online at www.worldwidewounds.com/2004/november/thomas. Accessed May 5, 2006.
4. Laufman H, Bongiovanni CM, Siegal JD, Boley SC. Scanning electron microscopy of moist bacterial strike-through of surgical materials. *Surg Gynec & Obstet*. 1980;150:165-170.
5. Altamirano AM. Reducing bacterial infectious complications from burn wounds. *Wounds*. 2006;Suppl, 17-19.